

# Anatomic Considerations on the Middle Ear in Dog

Carmen Berghes, Monica Parvu, Mircea Cucoanes, Daniel Cuca

Univeresity Spiru Haret, Faculty of Veterinary Medicine, Masina de Paine str. Nr.47,sector 2 Bucharest, Romania

---

## Abstract

Purpose of this study is to explain some aspects of middle ear anatomy in dog. The study was conducted on five dog skulls (different ages) from common, large size dogs. The skulls were processed by maceration and submitted to a treatment of mechanical cleaning with perhydrol. The temporal bone was collected first; the external wall was opened carefully to study the tympanic cavity. The ossicles were collected separately and subsequently described. From research carried promontory appears as an elongated projection that separates the oval window and round window. Vestibular window is oval or slightly ovoid shape of a hole, located dorso-medially to the promontory, which communicates with the middle ear vestibule. Cochlearia window appears as a round or circular hole located caudo-lateral to the promontory . it is blocked by a membrane called the tympanum secondary, cavity separating the ramp of the snail. In the ventro-oral cavity openings ductus faringo tympanicum. The osicules sound represented by hammer, anvil and stirrup are articulated with each other and form a chain as a link between the eardrum and vestibular window. Bones are driven by two muscles: the tensor muscle and muscle stirrup eardrum is very thin. osicules ear are relatively large and resemble those of humans. Lenticular bone is the lenticular process of the long arm of anville.

**Key words:** ear, hammer, anvil, ladder muscle

---

## 1. Introduction

The middle ear forms together with the external ear and inner ear the peripheral receiver of the auditory system and of the vestibular system. The literature has references to the middle ear of the domesticated mammals, but there is few descriptive data on the middle ear of the dog. The middle ear is an air-filled cavity (tympanic cavity) carved out of the temporal bone between the tympanic and stony parts, lined with mucous. The cavity holds for, articulated ossicles. The *tympanic membrane (eardrum)*, is an oval membrane, thin and resistant, separating the external ear from the middle ear; it has a more or less oblique position according to the species. It has a tensed part inserted on a fibro-cartilaginous

ring and a flaccid part. The tympanic cavity is oval, with two walls: external and internal, with a concave aspect and a circumference. The side wall is membranous and it consists of the tympanic membrane and the tympanic ring. The middle wall consists of the stony part of the temporal bone and it has three characteristic anatomic parts: the *promontory*, *oval widow* and *round window*. The *promontory* has an elongated prominence which separates the oval window from the round window. The *oval widow* or vestibular window, is like a slightly ovoid orifice, located dorso-medial from the promontory, by which the vestibule communicates with the middle ear. The *round window* or the cochlear window is a circularly orifice, located caudo-lateral from the promontory [1, 2]. It is covered by a membrane, the *secondary tympanum*, which separates the tympanic cavity from the tympanic ramp of the cochlea. On the ventro-oral side, the tympanic cavity has the tympanic opening [3, 4].The ossicles, hammer

---

\* Carmen Berghes ,tel. 04 0746252434, fax: 040212421576, email: [carber63@yahoo.com](mailto:carber63@yahoo.com)

(malleus), anvil (incus), round bone and the stirrup (stapes) form a chain linking the tympanum and the vestibular window. The ossicles are driven by two muscles: the *tensor muscle of the tympanum* and the *stirrup (stapes) muscle*. The mucous lining the cavity is continued with the throat/nasopharynx mucous via the Eustachian tube. [5, 6, 7, 8].

## 2. Materials and methods

The study was conducted on five dog skulls (different ages) from common, large size dogs. The skulls were processed by maceration and submitted to a treatment of mechanical cleaning with perhydrol. The temporal bone was collected first; the external wall was opened carefully to study the tympanic cavity. The ossicles were collected separately and subsequently described.

## 3. Results and discussion

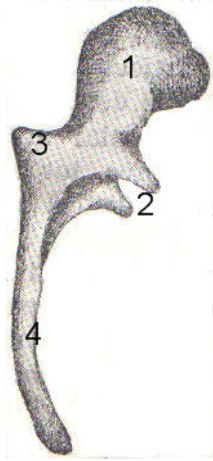
The **middle ear** is located inside the tympanic part of the temporal bone, being delimited medially by the stony part of the temporal bone. The tympanum cavity has two walls and a circumference. The external wall is closed by the tympanic membrane (ear drum) which separates the external ear from the middle ear. The *tympanic membrane* has an elliptical form, it is inserted obliquely, ventro-dorsally on the tympanic ring; it is concave towards the exterior and convex towards the interior. The *tympanic ring* is located on the external side of the tympanic cavity and has an oval shape. The internal wall is formed by the bony part of the stony portion of the temporal bone. Several formations can be observed on this wall: the *promontory*, which is a bony prominence looking like a mammilla, which separates the oval window from the round window and it belongs to the basal prominence of the cochlea; the *oval window* is located in front of the promontory. It is a small oval opening through which the tympanic cavity communicates with the vestibule. The base of the stirrup, the footplate, fills the oval window. The *round window* is larger than the oval window and is located posterior to the promontory. It has a circular opening corresponding to the tympanic ramp and it is covered by a membrane, the secondary tympanic membrane. The circumference of the tympanic cavity is made of an almost smooth bone, divided in the middle by a

thin relief which separates the cavity in two compartments. Inside the tympanic cavity there are the following ossicles: the *hammer (malleus)* is the longest of the ossicles and has two ends, an upper end and a lower end. *The head of the hammer* – the upper end – is rather irregular than round, and it joins the inside of the eardrum. Its caudo-ventral part has a joining area fitting to the anvil (incus). *The neck of the hammer* is quite long. Its external part relates to the upper part of the tympanic membrane (eardrum). *The arm of the hammer* – the lower end – is long and fits perfectly to the tympanic membrane ending in a spatula-shape. The arm of the hammer has two sides, anterior and posterior and two edges, lateral and medial. In its dorsal part the hammer has two processes, one short and thick and the other longer and thinner. The short and thick process is located laterally, it has the shape of a conic prominence and emerges from the ventro-lateral side of the hammer – this is the *lateral process*. The long process is located rostrally, close to the tympanic ring – this is the *rostral process* (fig. 1); the *anvil (incus)* is located ventro-medial from the hammer. It has a body and two arms. The *body of the anvil* has two sides: lateral and medial. The anterior part of the body has a joining facet which fits to the joining head of the hammer. The two arms are a horizontal one and a vertical one. The horizontal arm has a triangular shape – this is the *short arm*. The vertical arm ends in an apophysis in the shape of a lens – this is the *long arm* (fig. 2); the *stirrup (stapes)* has the shape of a saddle stirrup; it has a head, a basis and two arms. The head has on the lateral end a small particular facet which fits the lens-shaped apophysis of the anvil. The footplate of the anvil consists of an oval bony plate filling the oval window. The arms of the stirrup, one caudal and one rostral, describe a slight curve (fig. 3).

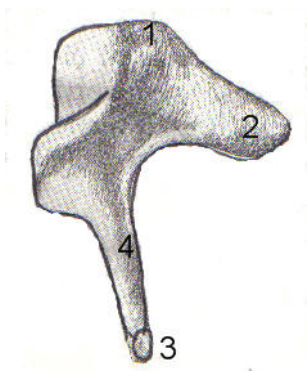
The middle ear ossicles are driven by the following muscles: *the hammer muscle* is an elongated muscle in the dogs. It originates close to the upper end of the pharynx-tympanum tube, goes upwards and ends in a tendon which recurves before the oval window to insert on the extremity of the long hammer apophysis. *The stirrup muscle* is a rather long, very thin muscle. It originates in the pyramidal tube where most part of it lies through a tendon inserted on the upper end on the stirrup head.

The middle ear communicates with the pharynx through the pharynx-tympanum tube, which is short – 1-1.5 cm – in the dogs and which has a

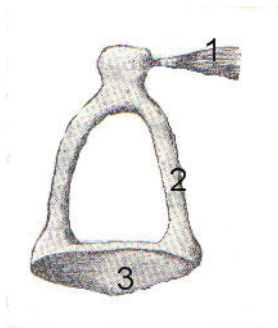
very elongated opening. This opening is rather difficult to reveal because of the mucous membrane covering it.



**Figure 1.** Hammer: 1- head; 2- rostral (long) process; 3- lateral (short) process; 4-arm; 5- muscular process.



**Figure 2.** Anvil: 1-anvil body; 2- short arm; 3- long arm



**Figure 3.** Stirrup: 1- muscle; 2- caudal arm; 3- footplate

#### 4. Conclusions

- 1.The tympanum cavity is very roomy and it is not lined with mastoid cells.
- 2.The ear ossicles are rather large and resemble very much to human ossicles.
- 3.The lens-shaped bone is represented by the lens-shaped process from the long arm of the stirrup.
- 4.The stirrup muscle is very thin, almost invisibly with the naked eye.
- 5.The pharynx-tympanum tube is short (1-1.5 cm).

#### References

Reference to a journal publication:

1. Balint Corneliu. Constituția urechii medii la câine. Teza de doctorat, 1929.
2. Ellenberger, W., und H. Baum. Handbuch der Vergleichenden Anatomie des Haustiere ed. XVI, 1926.
3. O. Navez. Precis D' anatomie descriptive du cheval. 1920.
4. Shambaugh G.E., Bloodstream in the labyrinth of the ear of the dog and man. Am. J.Anat. 1923, 32-189.
5. Schaller,O. (Editor): Illustrated Veterinary
6. Anatomical Nomenclature, F. Enke Verlag, Stuttgart 1992;
7. Tudor, D; Ghe. M. Constantinescu: Nomina Anatomica Veterinaria, Ediția a IV-a bilingvă, Editura Vergiliu, București, 2002.
8. Acherson G.H., The topographical anatomy of the smooth muscle of the cat's nictating membrane. Anat. Rec., 1938, 71-297.