

## COMPARATIVE ANATOMICAL STUDIES ABOUT CHICKEN SUB-BASAL CONNECTIONS

### STUDIUL ANATOMIC COMPARATIV PRIVIND CONEXIUNILE SUBBAZALE LA GAINA

CARMEN BERGHES, MONICA PARVU, D.CUCA, M. CUCANES

University "Spiru Haret", Faculty of Veterinary Medicine  
[carber63@yahoo.com](mailto:carber63@yahoo.com)

*The studies aimed to describe the nervous formations from the base of the cranium in the hen and domestic duck. These clarifications are necessary in order to disclose some unknown facts regarding this region in the poultry species used preponderantly in laboratory studies of the aviary flu.*

*The vegetative connections from the base of the skull have been studied on 10 poultry specimens, 5 hens and 5 ducks. The animals have been euthanatized using chloroform and a special dye has been injected through the heart in order to achieve a better differentiation of the nervous formations. Dissection was performed under a magnifying glass using instruments adequate to highly fine dissections. Photos and sketches of the dissected pieces have been taken. Nomina Anatomica (2003) was used to describe the observed formations. The studies showed that the cranial cervical ganglia around which is the sub-basal nervous tissue, is located on the border of the occipital hole, at the basis of the temporal pyramid, much deeper than in mammals; it is better developed in the duck (3-4 mm) than in the hen (1-2 mm); the cranial cervical ganglia has the shape of a globe in gallinaceans and it is long in shape in the ducks. A multitude of connecting branches were observed around the lymph node, linking it to the vague nerve, to the hypoglossal nerve, to the glosso-pharyngeal nerve and to the transversal paravertebral chain which is specific to poultry; an obvious branch detaches from the cranial pole, which is the sub-basal connective, while the cervical connective detaches from the caudal pole, connecting it to the cervical-thoracic lymph node.*

**Keywords** – subbasale conective, chicken, cranial cervical ganglia

## **Material and Methods**

The investigations were performed on 10 poultry specimens: 5 hens and 5 domesticated ducks of different ages. The cervical-cephalic area has been investigated by dissection under a magnifying glass. The joint carotid artery has been injected with a dyestuff in order to differentiate the vascular formations from the nervous formations. Sketches were made of the dissected parts. *Nomina Anatomica* (2003) was used to describe the observed formations.

## **Results and Discussion**

Like all animals, birds need a control centre and a set of communication channels to ensure that their system runs smoothly. As in most more complicated animals this is usually called a brain and a nervous system (Miclea, 1970). Birds have a similar basic plan to their nervous system as the rest of the vertebrates. The central nervous system is made up of a brain, a spinal chord and nerves. The brain is situated inside the skull and connected to one end of the spinal chord which as its name suggests runs down the centre of the spinal column. The nerves are bundles of neurones - a neurone is a single cell which transmits a micro-electrical pulse from one end of itself to the other. Neurones come in two sorts, sensory and motor. Sensory neurones are little alarms triggered by a variety of sense organs; eyes, ears, bristles, etc. They carry the messages to the brain that the bird uses to build up and maintain its image of the world. Motor neurones transmit messages the other way - from the brain to the muscles. Birds also have what is called an autonomic nervous system, which as in mammals and reptiles controls such essential actions as heartbeat, breathing and digestion. This can be divided into two sections; the sympathetic nervous system and the parasympathetic system. The sympathetic nervous system works in harmony with the endocrine system and the release of adrenaline and noradrenaline to stimulate a rapid response to danger. This is often called the 'fight or flight' reflex as it determines when a bird decides to make a rapid exit from the awareness of a predator. The parasympathetic system is made up of a series of groups of ganglia situated near various important organs such as the heart, lungs and digestive organs. These it controls and regulates with only occasional input from the brain (Akester, 1979).

The results of the study have revealed a morphological and topographical variability of the cervical cranial ganglia (Fig. 1). The cervical cranial ganglia is located in the domesticated duck at 0.6 cm (3 cases) and 0.8 cm (3 cases) from the occipital hole. It has a long shape and dimensions between 0.4-0.6 cm. It is bordered ventrally by the glosso-pharyngeal and ventrally by the vague nerve. It is oriented transversally, ventral-caudally. The internal carotid nerve detaches from the anterior pole and the carotid connective is linked to the posterior pole. The jugular nerve (which is a connective branch with the hypoglossal nerve) detaches from the dorsal border, a connection with the vague nerve and the transversal connective which is the connection branch with the transversal ganglionic chain.

The connective branches with the glosso-pharyngeal nerve, with the facial nerve and the branches forming the external and joint carotidal plexus detach from the ventral border of the lymph node. The cervical cranial lymph node is much smaller in the hen (0.2-0.3 cm). It generally has the shape of a globe (5 cases) or slightly prolonged (one case). From the anterior pole a fine internal carotidal nerve detaches, as well as connecting branches with the facial nerve; from the posterior pole a connecting branch with the vague nerve (which forms the jugular nerve) detaches, as well as the transversal connective and the carotidal connective. The connective branch with the hypoglossal nerve detaches from the upper border and the connective branch with the glosso-pharyngeal nerve detaches from the ventral border.

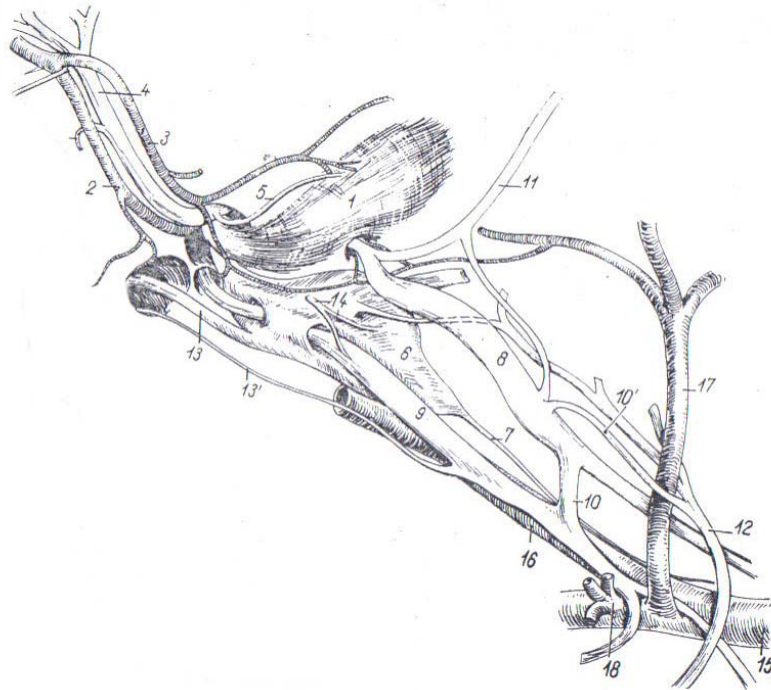


Fig.1 – 1-muschiul brahiocefalic, 2- a. meatului acustic extern, 3- r. musculara, 4- n. facial, 5 – n. muscular, 6 – ggl cervical cranial, 7 – conectivul carotic, 8 – n. vag, 9 – n. glosofaringian, 10 – r. comunicanta, 11 – n. accesoriu, 12 – n. hipoglos, 13- n. sfenopalatin, 15 – a. carotida comuna, 16a. carotida interna, 17 – a. occipitala, 18 – a. cervicala superioara

### Conclusions

- the cervical cranial lymph node of the domestic duck is larger, it ranges between 0.6-0.8 cm in size and it has a prolonged shape;

- the cervical cranial lymph node of the hen is smaller, it ranges between 0.2-0.3 cm in size and it has the shape of a globe;
- the carotid nerve detaches from the ventral extremity of the lymph node in the domestic duck;
- the jugular nerve, the carotid nerve and the transversal nerve detach from the ventral extremity of the cervical cranial lymph node in the hen.

### **References**

1. Akester A.R., 1979, The Autonomic Nervous System, *Form and Function in Bird*, Academic Press, Vol. I, 381-441.
2. Berghes Carmen, Damian A., 2006, Plexul celiomezenteric date comparative la struț și curcan. Clujul medical veterinar –*Revistă de medicină veterinară*, Cluj-Napoca, nr.9.
3. Ghetie V., St. Chitescu, V. Cotofan, A. Hillebrand, 1976, *Atlas de anatomie a pasarilor*, ed. Academiei R.S.R.
4. Miclea M. Sistemul neurovegetativ la pasarile domestice, 1970, *Teza de Doctorat, Fac de Med. Vet*, Bucuresti;