

Histological Changes of Cartilage Degeneration in Osteoarthritic Rabbits

Svätoslav Hluchý¹

^{1*} *Slovak University of Agriculture, Faculty of Agrobiological and Food Resources,
Nitra-94976, Tr. A. Hlinku, 2, Slovakia*

Abstract

The objective of this research was to evaluate the effect of glucosamine sulfate on histological changes of articular cartilage degeneration in rabbits. Knee joints during development of osteoarthritis in rabbits following collagenase-induced osteoarthritis were investigated. A total of 32 New Zealand White male and female rabbits were used in this study. All animals were kept in standard conditions at Research Institute of Livestock Production in Nitra. Animals were divided into 4 groups: healthy control group, osteoarthritic untreated group and two experimental groups. After collagenase-induced osteoarthritis daily oral administration of glucosamine sulfate (80 mg.kg⁻¹ and 160 mg.kg⁻¹ of live weight) was performed. After completion of the experiment, rabbits were subjected to euthanasia. After euthanasia, femur and fibula together were dissected for morphological and histological examination. Histopathological degeneration was assessed from histological slides. All parameters evaluated in osteoarthritic groups have specific stage of development of osteoarthritis, thickening of cartilage surface, cartilage thickness, number and distribution of chondrocytes and overall morphology. Morphological and histological evaluation of the femoral condyles in glucosamine-treated groups showed a lower extent and severity of the destruction of the cartilage in comparison with osteoarthritic control group.

Keywords: glucosamine sulfate, histology, knee joint, osteoarthritis, rabbit.

1. Introduction

Osteoarthritis is thought to be the most prevalent chronic and disabling joint disease in animals and humans and its treatment is a major orthopaedic challenge because there is no ideal drug treatment to preserve joint structure and function, as well as to ameliorate the symptomatology of the disease [1, 2]. Osteoarthritis is a chronic disease characterized by irreversible damage to joint structures, including loss of articular cartilage, osteophyte formation, alterations in the subchondral bone and synovial inflammation. It has been shown that chondroitin sulfate interferes with the progression of structural changes in joint

tissues and is used in the management of patients with osteoarthritis [3, 4].

2. Materials and methods

Laboratory animals were kept under standard conditions in an approved experimental facility of Animal Production Research Centre Nitra. Male and female New Zealand white rabbits of average live weight 2500±100 g were used in the experiment. Animals were divided into 4 groups: healthy control group, osteoarthritic untreated group and two experimental groups. After collagenase-induced osteoarthritis, daily oral administration of glucosamine sulfate (80 mg.kg⁻¹ GS1 group and 160mg.kg⁻¹GS2 group of live weight) was performed. Test substances were applied from the first day of the experiment. Treatment lasted a total of 60 days. Original

* Corresponding author: Svätoslav Hluchý
Email: svatoslav.hluchy@uniag.sk

glucosamine sulfate with a molecular weight of 456.42 (Rottapharm, Ltd) was used. The solutions were prepared fresh before each administration to animals. Glucosamine sulfate was administered orally to rabbits through the probe a daily basis. Osteoarthritis was induced by applying 0.5 ml of collagenase ($1.5 \text{ mg}\cdot\text{ml}^{-1}$) (Sigma-Aldrich Chemie GmbH) in saline intraarticular injection into the right and left knee joint of rabbits. Water for injection purposes in healthy control animals and untreated osteoarthritic control animals was used. After completion of the experiment, rabbits were subjected to euthanasia. Histopathological degeneration of cartilage were evaluated in the medial and lateral femoral condyle of the right and left knees by histological slides by [7]. Stereoscopic microscope (Olympus S240) and 4-point scale according to the modified method [5, 6] were used. The samples were fixed in 70% ethanol and decalcified at room temperature in a solution of EDTA at pH 7.6. Subsequently samples were dehydrated in ascending alcohol and mounted by the system Technovit 7100 (Heraeus Kulzer GmbH). The samples were cut on a rotary microtome AO Rotary Microtom 820 (American Optical Company, USA). The sections thick 3-5

μm stained with base fuchsin (BF) transparent staining - toluidine blue (TB) by Hayata [8] on chondrocytes and then safranin O as specific staining for proteoglycans. Microscope Jenaval (C. Zeiss) and modified camera Olympus were used for histological examination.

3. Results and discussion

Histological evidence of cartilage degeneration was found in treated and untreated groups of rabbits with induced osteoarthritis. The surface layer of articular cartilage in a group of healthy controls was smooth, without erosions, fibrillation and fissures with predominantly normal histological appearance. Cartilage matrix was undamaged, entire and arrangement of chondrocytes showed no degenerative changes (Figure 1). The articular cartilage of osteoarthritic groups showed degenerative changes such as the roughened surface, loss of the surface layer, erosion, fibrillation and fissures, irregular arrangement of chondrocytes or chondrocyte loss (Figure 2).

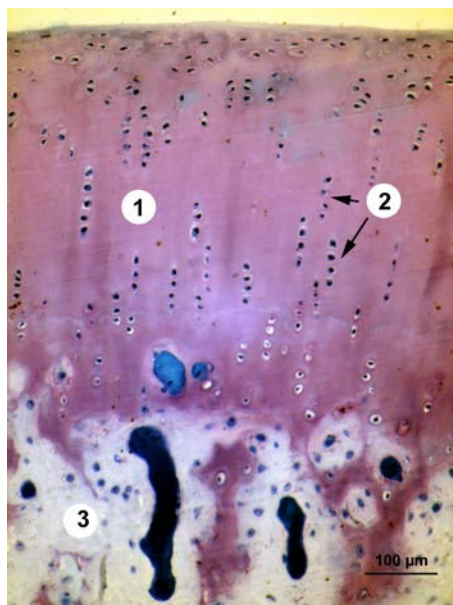


Figure 1. Microscopic structure of rabbit cartilage (healthy control) (BF+TB; 250 x)
1-hyaline cartilage (matrix), 2-chondrocytes (subchondral layer), 3 periosteum

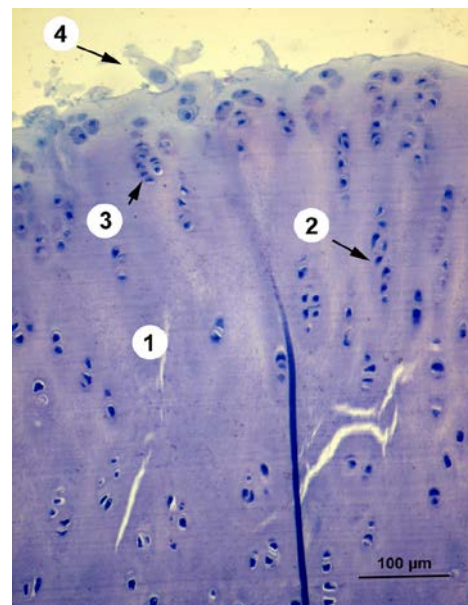


Figure 2. Microscopic structure of the cartilage of the rabbit (osteoarthritic group) (BF+TB; 250 x).
1-hyaline cartilage, 2-regular arrangement of chondrocytes, 3-chondrocytes grouped (character of degeneration), 4-rough surface cartilage

Necrotic chondrocytes (without nuclear staining) were observed infrequently and sporadically occurring together with hypertrophic (enlargement) and hyperchromic (hyperfunctioning) chondrocytes.

All parameters evaluated in osteoarthritic groups have specific stage of development of osteoarthritis, thickening of cartilage surface, cartilage thickness, number and distribution of chondrocytes and overall morphology. Morphological and histological evaluation of the femoral condyles in glucosamine-treated groups

showed a lower extent and severity of the destruction of the cartilage in comparison with osteoarthritic control group.

The osteoarthritic groups treated with glucosamine (GS1) visible loss of the cartilage surface with visible erosions were found. Chondrocytes were formed into groups in bunches and the disorganization was evident (Figure 3).

The osteoarthritic group treated with glucosamine (GS2), thickened surface with fissures (cracks) was observed. Chondrocytes were grouped into bundles (Figure 4).

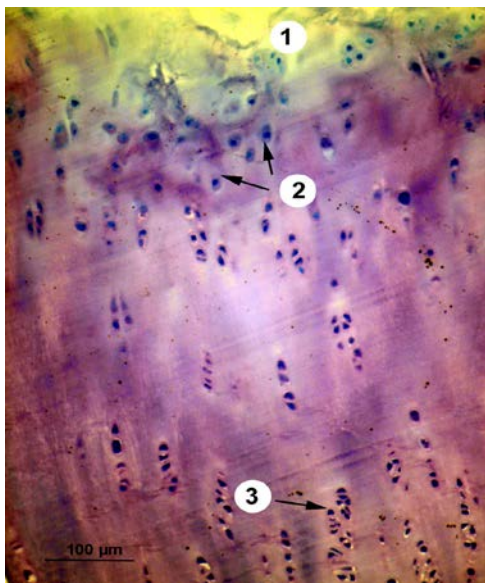


Figure 3. Microscopic structure of rabbit cartilage (GS1) (BF+TB-250 x) 1-loss of the surface layer, 2-disorganization of chondrocytes, 3-chondrocytes drafted into groups (bunches)

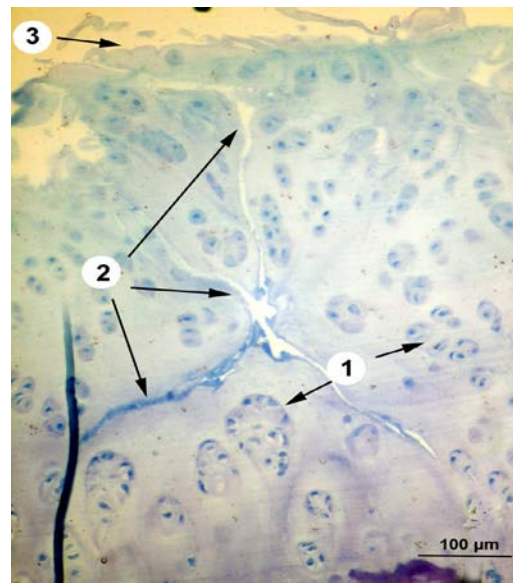


Figure 4. Microscopic structure of rabbit cartilage (GS2) (BF+TB -250x) 1-chondrocytes arranged in groups 2-fissures (cracks), 3-rough surface

The severity of damage of the articular cartilage surface was generally lower in the groups treated with glucosamine sulphate compared to osteoarthritic group. We can conclude that the severity of damage to the articular cartilage during development of osteoarthritis in the knee joints of rabbits proportionally decreased with increasing doses of glucosamine sulfate. Similar results have been documented by Kim et al. [9], Permuy et al. [10], Henrotin et al. [11], Silva et al. [12] and Lippiello et al. [13] in the experiment with the enzyme-induced osteoarthritis in the rabbit. On the other hand, Roman-Blas et al. [14] stated that combined therapy with chondroitin sulfate plus glucosamine sulfate or chondroitin sulfate plus glucosamine hydrochloride does not improve joint damage in an experimental model of knee

osteoarthritis in rabbits. Desando et al. [15] was studying biodistribution of an intra-articular injection of mesenchymal stromal cells (MSCs) and bone marrow concentrate (BMC) in a rabbit OA model and whether the additional use of sodium hyaluronate (HA) could modulate their migration and delay joint degeneration. Roman-Blas et al. [14] found that therapies of chondroitin sulfate plus glucosamine sulfate or chondroitin sulfate plus glucosamine hydrochloride failed to improve structural damage or to ameliorate the inflammatory profile of joint tissues during experimental osteoarthritis. Analgesics and nonsteroidal antirheumatics drugs plays vital role in improve pain and joint function [16]. Symptomatic effect is not based on the inhibition of prostaglandin synthesis - the essence of their

activity is the interference with the metabolism of joint cartilage, wherein the stimulating anabolic processes (synthesis of collagen and proteoglycans) and inhibits catabolic processes. This mechanism of action leads to the improvement of the symptoms of osteoarthritis [17]. Some drugs of this class (glucosamine sulphate, hyaluronic acid) have demonstrated the anti-inflammatory effect. Not acting via inhibition of cyclooxygenase II. Their anti-inflammatory effects caused by inhibition of inflammatory cytokines and oxygen free radicals by stimulating the synthesis of proteoglycans and by reducing the activity of proteolytic enzymes. They do not have serious side effects. They are chondrotrophic, it means that is taken up in cartilage and positively affects the function and metabolism of chondrocytes [18]. Chondroitin sulfate and glucosamine sulfate increase type II collagen and proteoglycan synthesis in human articular chondrocytes and are able to reduce the production of some pro-inflammatory mediators and proteases, to reduce the cellular death process and improve the anabolic/catabolic balance of the extracellular cartilage matrix [11, 19, 20]. In experimental animal models, the glucosamine sulfate is able to slow the development of osteoarthritis.

4. Conclusions

Differences between the control groups and experimental groups were statistically significant. The severity of articular cartilage damage during development of osteoarthritis in the knee joints of rabbits proportionally decreased with increasing doses of glucosamine sulfate.

These results demonstrate the chondroprotective effects of glucosamine sulphate in the experimental model in rabbits and suggest that this dosage may be useful to control the joint catabolic effects of inflammatory stress. These findings could have clinical relevance related to the prevention of joint degradation by glucosamine sulphate. Chondroitin sulfate is an effective and safe treatment option for patients with osteoarthritis.

Acknowledgements

This work has been supported by VEGA project No. 2/0037/16 (Ministry of Education, Slovak Republic).

References

1. Permuy, M., Guede, D., López-Peña, M., Muñoz, F., Caeiro, J. R., González-Cantalapiedra, A., Comparison of various SYSADOA for the osteoarthritis treatment: an experimental study in rabbits, *BMC Musculoskelet Disord.*, 2015, 20, 16, 120.
2. Bruyere, O., Reginster, J.Y., Glucosamine and chondroitin sulfate as therapeutic agents for knee and hip osteoarthritis, *Drugs.Aging.*, 2007, 24(7), 573-80.
3. Hochberg, M., Chevalier, X., Henrotin, Y., Hunter, D. J., Uebelhart, D., Symptom and structure modification in osteoarthritis with pharmaceutical-grade chondroitin sulfate: what's the evidence?, *Curr Med Res Opin.*, 2013, 29(3), 259-67.
4. Owens, S., Wagner, P., Vangsness, C. T Jr., Recent advances in glucosamine and chondroitin supplementation, *J Knee Surg.*, 2004, 17(4), 185-93.
5. Yoshioka, M., Coutts, R. D, Amiel, D., Hacker, S. A., Characterization of a model of osteoarthritis in the rabbit knee, *Osteoarthritis Cartilage.*, 1996, 4 (2), 87-98.
6. Yoshioka, M., Effects of single intra-articular injection of cross-linked hyaluronate hydrogel (Gel-200) on the anterior cruciate ligament (ACL) transection induced arthritis in rabbits, *Osteoarthritis Cartilage*, 2006, 14 (12), 49-50.
7. Kikuchi, T., Sakuta, T., Yamaguchi, T., Intra-articular injection of collagenase induces experimental osteoarthritis in mature rabbits, *Osteoarthritis Cartilage.*, 1998, 6(3), 177-86.
8. Hayata, I., Removal of stainable cytoplasmic substances from cytogenetic slide preparations, *Biotech. Histochem.*, 1993, 68(3), 150-2.
9. Kim, J., Chung, J., Ok, H., Asymptomatic acromioclavicular joint arthritis in arthroscopic rotator cuff tendon repair: a prospective randomized comparison study, *Arch Orthop Trauma Surg.*, 2011, 131(3), 363-9.
10. Permuy, M., Guede, D., López-Peña, M., Muñoz, F., González-Cantalapiedra, A., Caeiro, J. R., Effects of glucosamine and risedronate alone

or in combination in an experimental rabbit model of osteoarthritis, *BMC Vet Res.*, 2014, 26, 10, 97.

11. Henrotin, Y., Marty, M., Mobasheri, A., What is the current status of chondroitin sulfate and glucosamine for the treatment of knee osteoarthritis?, *Maturitas*, 2014, 78(3), 184-7.

12. Silva, F. S Jr, Yoshinari, N. H., Castro, R. R., Girão, V. C., Pompeu, M. M., Feitosa, J. P., Rocha, F. A., Combined glucosamine and chondroitin sulfate provides functional and structural benefit in the anterior cruciate ligament transection model, *Clin Rheumatol.*, 2009, 28(2), 109-17.

13. Lippiello, .L, Woodward, J., Karpman, R., Hammad, T. A., In vivo chondroprotection and metabolic synergy of glucosamine and chondroitin sulfate, *Clin Orthop Relat Res.*, 2000, (381), 229-40.

14. Roman-Blas, J. A., Mediero, A., Tardío, L., Portal-Núñez, S., Gratal, P., Herrero-Beaumont, G., Largo, R., The combined therapy with chondroitin sulfate plus glucosamine sulfate or chondroitin sulfate plus glucosamine hydrochloride does not improve joint damage in an experimental model of knee osteoarthritis in rabbits, *Eur J Pharmacol.*, 2017, 5, 794, 8-14.

15. Desando, G., Bartolotti, I., Cavallo, C., Schiavinato, A., Secchieri, C., Kon, E., Filardo,

G., Paro, M., Grigolo, B., Short-Term Homing of Hyaluronan-Primed Cells. Therapeutic Implications for Osteoarthritis Treatment, *Tissue Eng Part C Methods.*, 2018, 24(2), 121-133.

16. Richette, P., Effect of hyaluronic acid in symptomatic hip osteoarthritis, *Arthritis Rheum.*, 2009, 60(3), 824-30.

17. Rovenský, J., Pavelka, K., *Klinická reumatológia, Clinical Rheumatology, slovak lang.*, Martin, Osveta, 2000.

18. Basleer, C., Henrotin, Y., Franchiment, P., In vitro evaluation of drugs proposed as chondroprotective agents, *Int J Tissue React.*, 1992, 14, 231-41.

19. Terencio, M. C., Ferrándiz, M. L., Carceller, M. C., Ruhí, R., Dalmau, P., Vergés, J., Montell, E., Torrent, A., Alcaraz, M. J., Chondroprotective effects of the combination chondroitin sulfate-glucosamine in a model of osteoarthritis induced by anterior cruciate ligament transection in ovariectomised rats, *Biomed Pharmacother*, 2016, 79, 120-8.

20. Lee, Y., H, Woo, J. H, Choi, S. J, Ji, J. D., Song, G. G., Effect of glucosamine or chondroitin sulfate on the osteoarthritis progression: a meta-analysis, *Rheumatol Int.*, 2010, 30(3), 357-63.